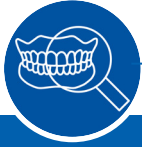

## A Fully Digital Workflow for a Full Arch Restoration in Both Jaws With SPI®ELEMENT Implants



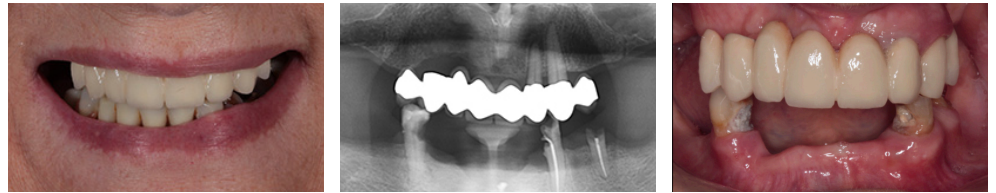
Dr. Luca Lavorgna, Italy



### The Baseline Situation

Patient with significant esthetic and functional impairments

A female patient with major dentophobia presented at the clinic with significant esthetic and functional impairments. She had lost most dental components and the upper prosthetic restoration showed obvious mobility. The patient's primary request was to conduct the entire surgical treatment in a single step in order to reduce emotional stress.

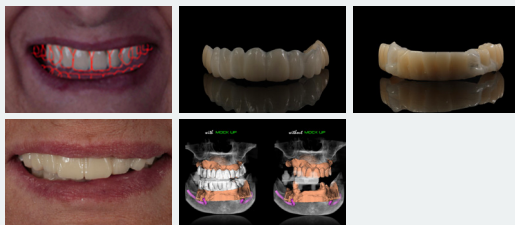


### The Treatment Strategy



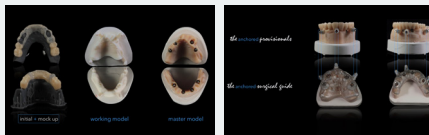
#### 1 Prototype mock-up and CBCT

Digital planning of the new smile and implant positions  
Confirmation of the correctness of the digitally retrieved esthetic and functional diagnosis with a 3D-printed mock-up  
Definition of therapeutic details within one appointment



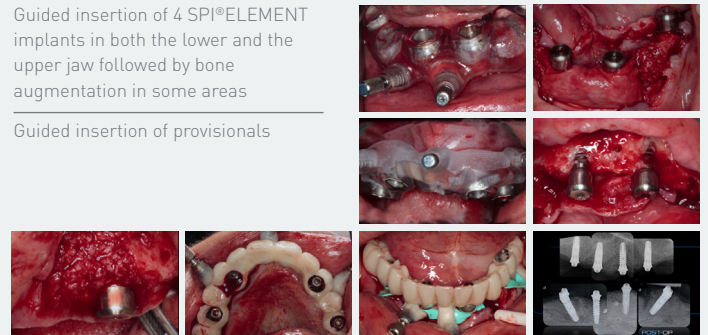
#### 2 Cross-mounting and design of surgical guide

Mounting of the prosthetic model according to functional parameters established with the mock-up  
Use of anchor pins for stable positioning of designed provisionals and surgical guide



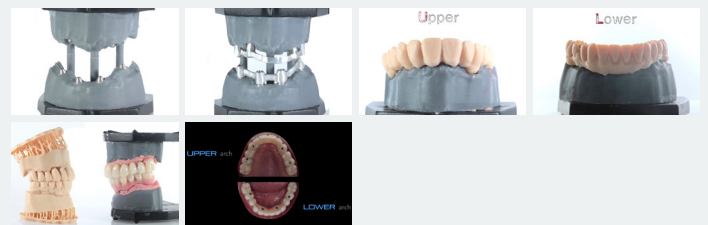#### 3 Guided surgery

Guided insertion of 4 SPI®ELEMENT implants in both the lower and the upper jaw followed by bone augmentation in some areas  
Guided insertion of provisionals



#### 4 Final screw-retained monolithic zirconia restorations

4 months after surgery, final design guided by initial mock-up



### The Outcome

At the 5-year follow-up, bone volumes were preserved, and the marginal soft tissue appeared stable. The keys to success in this case were a proper prosthetic planning, adherence to the plan by appropriate therapeutic approaches, and the use of an implant system with a conditioned surface and a stable connection.

